

# A robust tissue-based standardization method of MR images

A. Carla<sup>1 2</sup> R. Cataldo<sup>1 3</sup> I. De Mitri<sup>1 2</sup> G. De Nunzio<sup>1 3</sup> M. Quarta<sup>1 4</sup> and the MAGIC-5 Collaboration

<sup>1</sup>Istituto Nazionale di Fisica Nucleare sez. di Lecce, Italy

<sup>2</sup>Department of Physics, University of Salento, Lecce, Italy

<sup>3</sup>Department of Materials Science, University of Salento, Lecce, Italy

<sup>4</sup>Department of Mathematics, University of Salento, Lecce, Italy

A well-known problem in MR image analysis is that intensities do not have a fixed tissue-specific numeric meaning, even within the same MRI protocol, for the same body region, or for images of the same patient obtained on the same scanner. The lack of a standard and quantifiable interpretation of the intensity scale compromises the precision, accuracy, and efficiency of some important post-processing tasks, such as, for example, segmentation and registration methods.

With the aim to address a robust method in giving similar intensities to similar tissues, even across MR images coming from different sources, a Tissue-Based Standardization technique (TBS) of MR brain images was developed. An important body of literature deals with the standardization of MR intensities [1–6]. Our technique is mainly inspired to Nyul and Udupa and their research group works over years. They used a two-step approach to standardize MR image intensity. The first step (training) involved the definition of a standard intensity scale as a sort of average derived from a set of images (or possibly from a single reference), and finding the parameters of the standardizing transform. The second step (transformation) applied the learnt transform to any new image to standardize its histogram, i.e. to map its intensity greyscale to the standard one. A similar approach is used in our work, introducing some novelties in order to minimize the risk of brain tissue mixing. A consistent number (about 500) of MR brain images downloaded from the Alzheimer’s Disease Neuroimaging Initiative (ADNI - web site <http://www.loni.ucla.edu/ADNI>) and the Open Access Series of Imaging Studies (OASIS - web site <http://www.oasis-brains.org>) were used to develop the procedure. In the original paper by Nyul and Udupa [1] mode-based landmarks were used to define the standard scale but, as later pointed out by the authors, it might happen that a particular mode corresponded, in two images A and B, to different matters (e.g. WM in image A, GM in image B). In this case, the mode should

not be used as a landmark, because it would lead to tissue mixing, i.e. different tissues would be projected to the same standard levels. The consequence of training with such landmarks would be to obtain a meaningless standard scale. For this reason, in subsequent papers other landmarks (the percentiles) were employed [2,3]. After coding and testing this standardization approach, we remarked that even when percentiles were used, the risk of tissue mixing was high. Figure 1 shows a typical case where tissue mixing, produced by inaccurate standardization based on percentiles, is evident, and would be inevitable. In that figure, the original histograms of two images acquired in different hospitals, from different patients, are shown as the thick continuous lines on top of each plot. The dotted line represents the sum of the three histograms for CSF, GM, and WM, calculated by segmentation of the images into the three main brain tissues. On these histograms a particular percentile (80%) was calculated as an example, and is marked by a dot on the x axis and labeled by P in both images. It is evident that (neglecting background contribution) the aforementioned landmark corresponds to almost pure WM in the right image, and to a mix of about 50% WM and 50% GM in the left one. If many MRI scans were taken for the training database similar to the right one, the averaged 8%-landmark would correspond to pure WM, and an image like the left one would undergo a conversion of part of its GM to WM. As a consequence, the choice of a percentile-based landmark does not insure stability. In our approach, this drawback is limited by separately applying the standardization procedure, after segmentation by an atlas, to the three main cerebral tissue classes, instead of the whole brain. Moreover, deciles are chosen as the histogram landmarks, so as to have a smoother map function. This standardization method has some strength points: it does not require MR images of known properties as reference material, it does not entail explicit manual sampling of different tissue regions, the standardiza-

tion method can be applied to any MRI protocol, for any body region, and can be used to correct for intra-/inter-patient, intra-/inter-scanner, and intra-/inter-site MR image intensity variations.

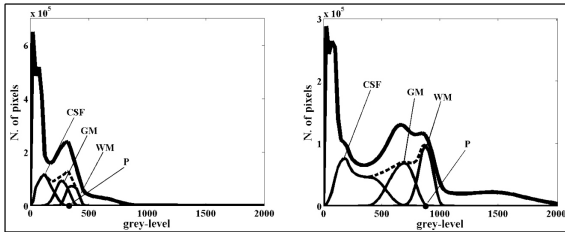


Figure 1. Risk of tissue mixing due by inaccurate standardization based on percentiles.

In order to evaluate the effectiveness of the applied technique, we compared the mean absolute error [6] of the original images and of the corresponding TBS-standardized ones, calculated as:

$$MAE = \frac{1}{N} \sum_{v=1}^N |I_{0,v} - I_{s,v}|$$

where  $N$  is the number of voxels, and  $I_{0,v}$  and  $I_{s,v}$  are intensity greyvalues for the test image (either standardized or the original one) and a reference image, at voxel  $v$ , after performing non-linear registration between the images. The reference images used throughout this study, for the creation of the standard scale and for MAE calculation, are both the MNI152 and the Colin 27 standard templates, high resolution ( $1\text{-mm}^3$  isotropic), high signal-to-noise average of respectively 152 and 27 T1-weighted images of a single human brain, with delineated CSF, GM, and WM tissue masks. The MAE value decreased after image standardization, so witnessing a significant result in obtaining similar intensities for similar brain tissues. This technique has already been employed, for example, within our procedure for generating a set of templates for the hippocampal region in MR images, representative of the clinical conditions of the population under investigation [7]. At present we are applying the procedure to other sequences (e.g. T2-weighted images), so that a more extensive comparison of the performance of this procedure with other methods of the literature will be possible.

**Acknowledgments** We thank the Alzheimer’s Disease Neuroimaging Initiative (ADNI) and Open Access Series of Imaging Studies (OASIS) for access to MRI data.

## REFERENCES

1. Nyul LG and Udupa JK. On Standardizing the MR Image Intensity Scale. *Magnetic Resonance in Medicine* 1999; 42:10721081.
2. Nyul LG, Udupa JK and Zhang X. New variants of a method of MRI scale Standardization. *IEEE Trans Med Imag* 2000; 19(2):143150.
3. Ge Y *et al.* Numerical tissue characterization in MS via standardization of the MR image intensity scale. *J Magn Reson Imag* 2000; 12(5):715721.
4. Leung KK *et al.* Robust atrophy rate measurement in Alzheimer’s disease using multi-site serial MRI: Tissue-specific intensity normalization and parameter selection. *NeuroImage* 2010; 50:516523.
5. Hellier P. Consistent intensity correction of MR images in Int Conf Image Process (ICIP) 2003; 1:11091112.
6. Robitaille N *et al.* Tissue-Based MRI Intensity Standardization: Application to Multi-Centric Datasets. Article in Press on International Journal of biomedical imaging.
7. Cataldo R *et al.* Generating a minimal set of templates for the hippocampal region in MR neuroimages. In Press on International Journal of Neuroimaging.